

14  
COMPLIMENTS OF  
DR. F. KRUG,  
13 EAST 41ST STREET,  
NEW YORK

# EXTIRPATION OF SARCOMATOUS OVARIES

IN A

## PSEUDO-HERMAPHRODITE.

BY  
FLORIAN KRUG, M.D.,


Gynecologist to the German Hospital, New York.

---

[Reprinted from the AMERICAN JOURNAL OF OBSTETRICS AND DISEASES  
OF WOMEN AND CHILDREN, Vol. XXIV., No. 1, 1891.]

---

NEW YORK:  
WILLIAM WOOD & COMPANY, PUBLISHERS,  
56 & 58 LAFAYETTE PLACE.  
1891.



# EXTIRPATION OF SARCOMATOUS OVARIES

IN A

## PSEUDO-HERMAPHRODITE.

BY

FLORIAN KRUG, M.D.,

Gynecologist to the German Hospital, New York.

---

[Reprinted from the AMERICAN JOURNAL OF OBSTETRICS AND DISEASES  
OF WOMEN AND CHILDREN, Vol. XXIV., No. 1, 1891.]

---

NEW YORK :  
WILLIAM WOOD & COMPANY, PUBLISHERS,  
56 & 58 LAFAYETTE PLACE.  
1891.

STATE OF NEW YORK

IN SENATE

January 10, 1894

REPORT OF THE

COMMISSIONERS OF THE LAND OFFICE

FOR THE YEAR 1893

ALBANY:

WILEY, PUBLISHERS, 1894.

ALBANY:

1894.

1894.

1894.

1894.

1894.

1894.

1894.

1894.

1894.

1894.

1894.

# EXTIRPATION OF SARCOMATOUS OVARIES

IN A

## PSEUDO-HERMAPHRODITE.<sup>1</sup>

---

THE rarity of the following case is my apology for reporting it.

The patient, a native of Poland, 19 years of age, was admitted to the German Hospital February 13th, 1889, and gave the following history:

Family history negative. As early as the tenth year of her age the patient had a copious growth of hair over the entire body, particularly on the face, and this latter to such an extent as to attract considerable attention and general comment. At the age of 16 the patient began to experience pains in the abdominal region at regular intervals of about four weeks; during that time there was also profuse epistaxis, but at no time any indication of a menstrual flow. A few months previous to her admission to the hospital the patient suffered continuous pain in the lower part of the abdomen, and at the same time became aware of the presence of a swelling, this compelling her to seek medical advice for the first time.

Her physician, after a hasty examination, sent her to the hospital with the diagnosis: hematometra et hemato-colpos duplex. On first seeing the patient in the gynecological ward I thought that, by mistake, a male had been placed there, so strikingly did she resemble one of the sterner sex; in fact, there was nothing suggestive of femininity about the patient

<sup>1</sup> Reported before the New York Academy of Medicine, Section on Obstetrics and Gynecology, October 23d, 1890.

except her long tresses. On closer examination and inquiry the following facts were revealed.

There was a strong growth of hair on the face, whiskers and moustache. The patient shaved herself daily. The entire body, particularly the anterior portion of the thorax, also the limbs, and the lower abdominal region, especially along the linea alba, were thickly covered with strong hair varying in length from one-half to one inch. The mammary glands were poorly developed. The bones were massive, and in their form and development presented all the characteristics of the male type; this was particularly noticeable in the extremities and pelvic bones. The larynx was protuberant and as prominent as we observe it in the male.

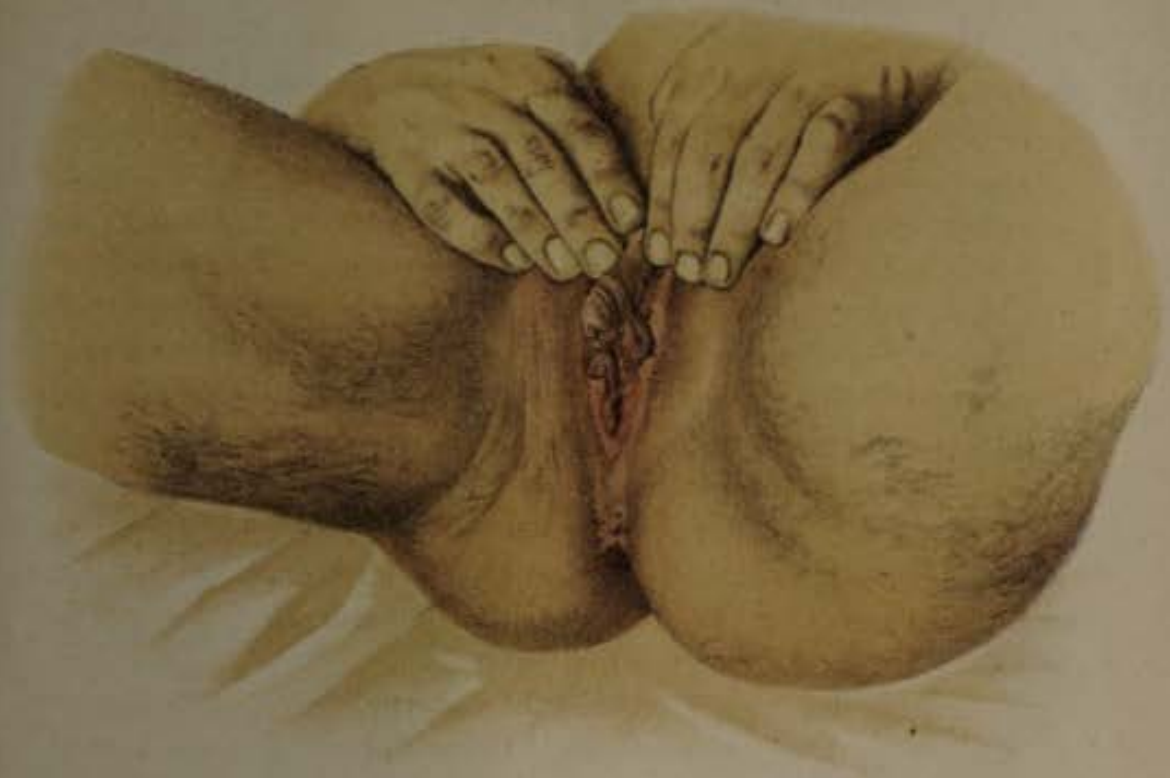The abdomen was enormously distended by a large, solid tumor which extended into the pelvis on both sides. Palpation determined the presence of a considerable quantity of ascitic fluid in the abdominal cavity.

At the first casual glance the external genitals strikingly resembled those of the male: there appeared to be a penis fully two inches in length, which was erectile on manipulation; immediately below, two folds closely resembling a longitudinally divided scrotum presented themselves. But the apparent penis was imperforate, and no testicles were contained within the integumental folds. Below this was detected a small entrance into a very narrow vagina, and on either side poorly developed labia. The urethra was situated directly below the penis-like clitoris. On introducing the finger into the very small vagina no rugæ could be detected. Immediately behind the symphysis pubis a very small portio vaginalis could be determined, the pinhole admitting a fine sound for a distance of about two inches. The tumor could readily be felt on both sides of, and posterior to, the small uterus, and extended as low down as the ischial spines, but could not be clearly differentiated from the body of the uterus.

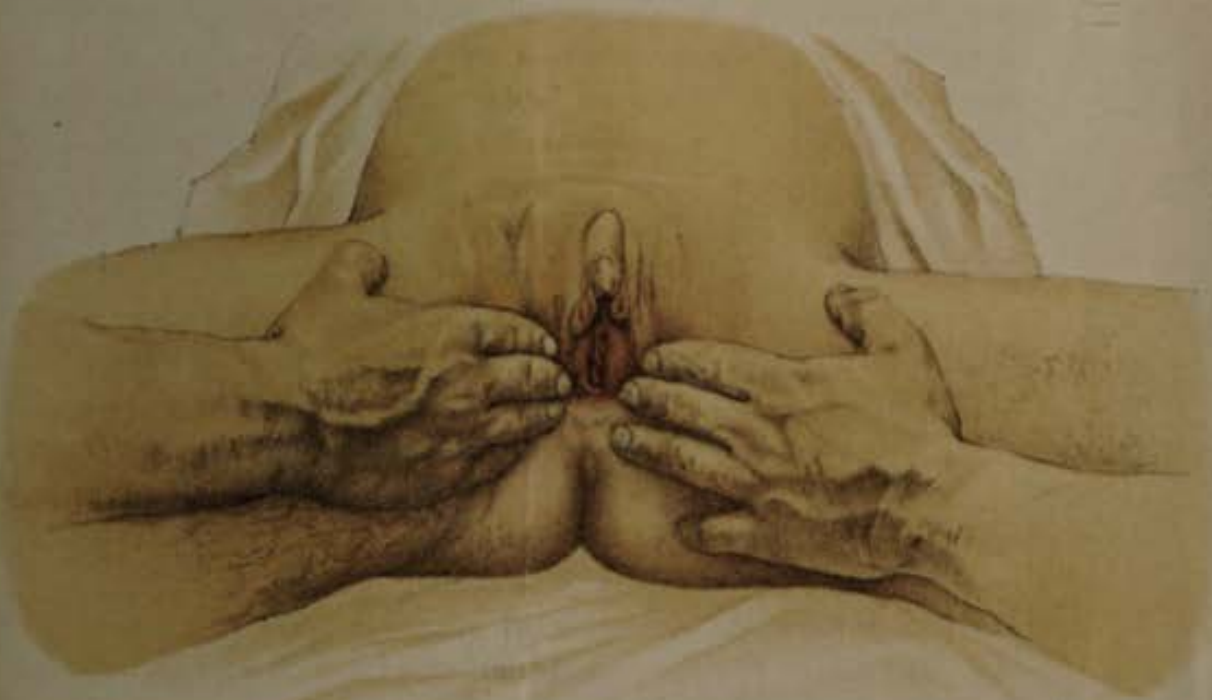A diagnosis of a probably malignant tumor of both ovaries in a pseudo-hermaphrodite was made.

Urinary examination revealed granular casts and considerable albumin. Physical examination of the chest revealed a


No 1.



No 2.



PSEUDO-HERMAPHRODITISMUS BILATERALIS EXTERNUS.  
ANGIOSARKOMA OVARIUM DUPLEX - K R U G .





systolic apical cardiac murmur and diffuse bronchitis. There was considerable edema of the legs, particularly of the right.

The general condition of the patient being a very poor one, operative interference, which alone could afford relief, was postponed, so that the patient might be brought into a suitable condition to withstand the effects of a serious surgical undertaking.

During this time endeavors were made in the direction of acquiring information relative to the sexual life of the patient, but she being of very limited intelligence, in fact mentally dull, all inquiry was of no avail.

In spite of every effort to improve her general condition, the patient grew worse daily; the abdominal tumor increased very rapidly in size; the pulse became more feeble, frequent, and intermittent; frequent respiration, persistent cough, occasional vomiting and diarrhea occasioned the patient considerable discomfort; the pains in the abdomen became so violent as to require the frequent administration of narcotics.

With such a condition of affairs I decided to operate without further delay. The patient was placed upon the operating table February 26th, 1889.

I debated for some time which anesthetic would be the more appropriate. Ether seemed to be contra-indicated owing to the renal affection and the marked bronchitis; again, I feared chloroform with such a marked cardiac weakness. Ether was finally decided upon as the lesser of two evils, but I regretted it later.

*Operation.*—An incision was made in the linea alba extending from the umbilicus to the symphysis pubis. On opening the peritoneal cavity a large quantity of ascitic fluid escaped. There were numerous adhesions between the tumors and the intestines, as well as with the parietes. These adhesions were divided with considerable difficulty, a number of ligatures being employed for that purpose. I now found that the lower portion of the tumor of the right ovary had unfolded the right broad ligament, and I was obliged to shell it out from the pelvis. I then made a short pedicle, tied and severed it close to the cornu of the uterus. The same condition existed on the left side, with the exception that the left tumor was smaller.

During the operation the hemorrhage was trifling; a drainage tube was considered unnecessary, and after a careful toilet of the peritoneal cavity the abdomen was closed in the usual manner.

The patient rallied well from the surgical shock, but on the following day well-marked symptoms of a double pneumonia were developed.

At no time after the operation were there any symptoms indicative of any intraperitoneal trouble—no distention or tenderness of the abdomen; there was free bowel evacuation; only slight vomiting during the first hours after the operation, dependent upon the administration of the anesthetic.

The pneumonia, however, made rapid progress, the pulse became accelerated, respiration 56, marked cyanosis. Of the physicians who saw the case, all were of the opinion that the inflammatory condition of the lungs was directly due to the ether administered at the time of operation.

All therapeutic efforts proved fruitless; the patient died ten days after operation.

I do not wish to introduce at length the subject of ether-pneumonia. Suffice it to say that I have met with five cases of pneumonia directly due to the administration of ether; of these cases, two ended fatally. Hence, when operative cases present themselves in which there is marked bronchial affection, I prefer the administration of chloroform.

To be brief, I shall present only the more important facts revealed at the autopsy.

The abdominal incision was well healed and the adjacent tissues perfectly normal. No fluid was present in the peritoneal cavity. The parietal and visceral peritoneum was smooth and glistening; no trace of any fibrinous exudate. The stumps on either side of the small uterus where the ligatures had been applied were perfectly normal. Both lungs were in a state of hepatization, with the exception of the apices. Considerable serum was present in the pleural cavity. Examination of the heart revealed the existence of a chronic endocarditis. The left kidney was enlarged, very anemic, though irregularly studded with hyperemic foci. The right kidney was also enlarged, but to a greater extent than the left, and was closely adherent and inseparable from a tumor, the size of a child's

head, in which it was embedded; a portion of the pancreas and the large vessels were also involved in this metastatic growth.

Microscopical examination, for which I am indebted to Dr. Adler, of this city, revealed the following facts: The primary tumors of the ovaries were of the nature of mixed growths. While in some places the appearance presented was that of simple round-cell sarcoma with moderately large cells, very little intercellular tissue, and enormously enlarged capillaries, in other spots the sarcomatous tissue seemed confined mainly to the immediate neighborhood of blood vessels. Around the heavily hypertrophied coats of the dilated vessels was seen an almost circular patch of sarcomatous material; these patches were surrounded and separated from similar patches by wide tracts of fibrous tissue, which latter frequently presented myxomatous, chondroid, and osteoid metamorphoses; here and there patches of simple calcareous deposit or calcification were found. Accordingly the tumors had to be classed as sarcoma fibromatosum, with secondary myxomatous, chondroid, and osteoid changes. The metastatic growth presented the uniform appearance of simple soft round-cell sarcoma.

Had no operative interference been undertaken, death would have inevitably followed in a short time, as the metastatic tumor involved the kidney, pancreas, and abdominal aorta; still it was hastened by the unfortunate occurrence of the complicating ether-pneumonia.

While hermaphroditism was formerly regarded as a mere freak of nature, to-day its etiology is more readily comprehended, for we know that at an early stage of fetal development the sexual organs are double in their preformations, and that the external organs of generation up to the fourth month of gestation present no apparent difference. It will be readily seen that all that is necessary to produce hermaphroditism is either the persistence of a part which should normally disappear, or the development of the genitals in the originally duplex character. Considering these circumstances, it is surprising that hermaphroditism does not occur more frequently.

Hermaphroditismus verus—the co-existence of functioning double sexual organs on one or both sides of the same

individual—has up to the present day not been established as proven; still there are quite a number of cases recorded in which there is a more or less pronounced degree of pseudohermaphroditism. In most cases the individual is possessed of internal male organs, whereas the external genitals and the general build and type are female in character.

Cases similar to the one described (properly termed pseudohermaphroditismus bilateralis externus femininus) are rare. The interesting question suggests itself: Is congenital anomaly of the sexual organs a predisposing factor towards the subsequent malignant degeneration of the same? Although this can be only a matter of conjecture, offering a wide field for speculation, it certainly appears to be a strong argument in favor of Cohnheim's theory of the embryonic preformation of neoplasms.



